

## Extracorporeal shock wave lithotripsy in a 10-month-old girl with staghorn calculus

António V. Silva<sup>1</sup>, Diana A. Moreira<sup>1</sup>, Armando Reis<sup>2</sup>, Filipe Rodrigues<sup>3</sup>, Graça Ferreira<sup>1</sup>, Eduarda Marques<sup>1</sup>, António Vilarinho<sup>1</sup>

<sup>1</sup> Department of Paediatrics, Centro Hospitalar Vila Nova de Gaia, Portugal.

<sup>2</sup> Department of Paediatric Urology, Centro Hospitalar do Porto, Portugal.

<sup>3</sup> Department of Urology, Centro Hospitalar de Trás-os-Montes e Alto Douro, Portugal.

Received for publication: 22/09/2011

Accepted in revised form: 27/01/2012

### ABSTRACT

**Introduction:** Urolithiasis is rare in developed countries. Staghorn calculi are a type of upper urinary tract stone that involves the renal pelvis and extends into at least two calyces. Although all types of urinary stones can potentially form staghorn calculi, approximately 75% are composed of a struvite matrix and are generally associated with urinary tract infection caused by urea-splitting bacteria. Curative treatment is possible only by eliminating all of the stone fragments and by eradicating urinary tract infections.

**Case Report:** We present a case of a 10-month-old girl with a staghorn calculus caused by multiple urinary tract infections. After urine sterilisation, extracorporeal shock wave lithotripsy was performed during separate sessions. Following her last treatment, the child is free of nephrolithiasis.

**Conclusion:** Struvite calculi should be considered in all children with *Proteus* urinary tract infection. Extracorporeal shock wave lithotripsy is an efficient and safe treatment in young children (<2 years) and should be considered as the first option.

#### Key-Words:

infant; lithotripsy; staghorn calculi.

### INTRODUCTION

The incidence, composition and clinical characteristics of urinary calculi in children vary greatly from one part of the world to another<sup>1-3</sup>. Urolithiasis is rare (incidence of 1-2 children per million total population per annum) in developed countries, where less than 1% of all renal stones occur in children younger than 10 and most stones have metabolic origin<sup>2</sup>.

Struvite calculi account for approximately 5-10% of stones in children<sup>2,4</sup>. The peak incidence is at 2 years old with predominance in males (80%)<sup>1,2,5</sup>. Staghorn calculi are a type of upper urinary tract stone that involves the renal pelvis and extends into at least two calyces<sup>6</sup>. Although all types of urinary stones can potentially form staghorn calculi, approximately 75% are composed of a struvite matrix (magnesium ammonium phosphate)<sup>7</sup>. Struvite calculi are generally associated with urinary tract infection (UTI). UTI caused by urea-splitting bacteria (*Proteus spp.*, *Klebsiella spp.*, *Pseudomonas spp.* and others) result in urinary alkalisation and excessive production of ammonia, which can lead to the precipitation of struvite and calcium phosphate<sup>7,8</sup>.

Curative treatment is possible only by eliminating all of the stone fragments and by eradicating UTI<sup>8,9</sup>. Staghorn calculi are unquestionably an indication

for interventional therapy (extracorporeal shock wave lithotripsy [ESWL], percutaneous nephrolithotomy, retrograde ureteroscopic stone disintegration using a holmium laser or open surgery)<sup>6</sup>. Conservative treatment is not an acceptable therapeutic option in this clinical situation<sup>6</sup>. A noninvasive approach such as ESWL is a safe and efficient treatment in children with staghorn calculi.

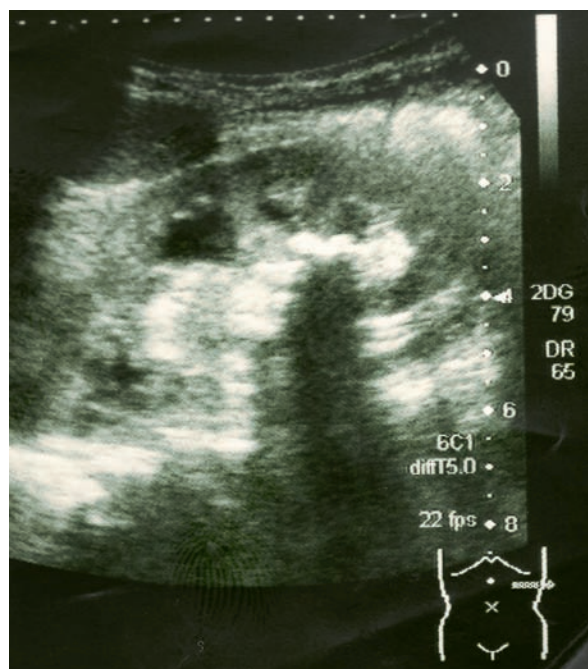
## CASE REPORT

A female, first-born baby of non-consanguineous parents, with normal antenatal ultrasound diagnosis, was delivered vaginally at 38 weeks gestation, with Apgar 8/9, with no need of reanimation. Anthropometry at delivery was appropriate for the gestational age.

At the age of five months, she experienced the first episode of pyelonephritis, which was promptly diagnosed and correctly treated. *Escherichia coli* was isolated from urine culture. Renal ultrasonography revealed bilateral mild ureterohydronephrosis. Prophylactic trimethoprim was initiated. Voiding cystourethrogram (VCUG) revealed vesicoureteral reflux (VUR) grade II at the right kidney. Screening for persistent bacteriuria after episode of UTI was negative.

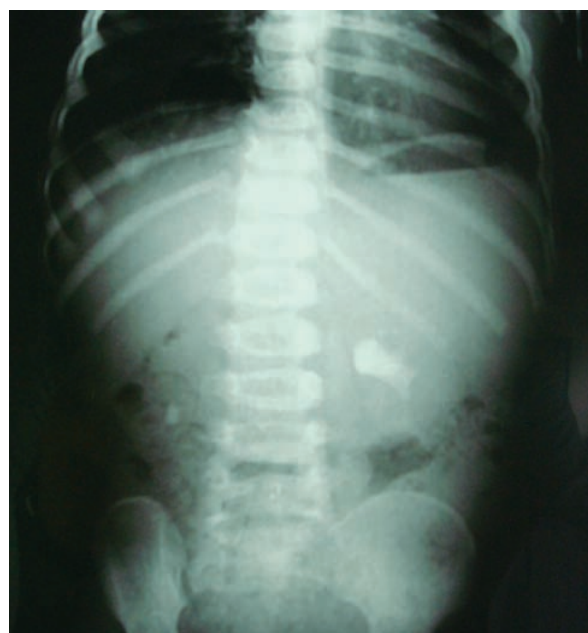At the age of nine months, she developed another episode of pyelonephritis and a *Proteus mirabilis* was isolated from urine culture. Renal ultrasonography revealed an echogenic calculus of seven millimetres (mm) at left renal pelvis.

At the age of ten months, she developed the third episode of pyelonephritis in five months. *Escherichia coli* was isolated from urine culture. Renal ultrasonography revealed a staghorn calculus at left renal pelvis (35 mm) associated with dilatation of calyces and a small calculus of 5mm at right renal pelvis (Fig. 1). A conventional abdominal radiograph confirmed the presence of a staghorn calculus at left renal pelvis and a round calculus at right renal pelvis (Fig. 2). Serum creatinine, calcium, phosphorus, uric acid, parathyroid hormone levels and urinary calcium, oxalate, uric acid and aminoacids were normal. Chemical analysis of stone passed in the urine after ESWL revealed magnesium and calcium phosphate (struvite).



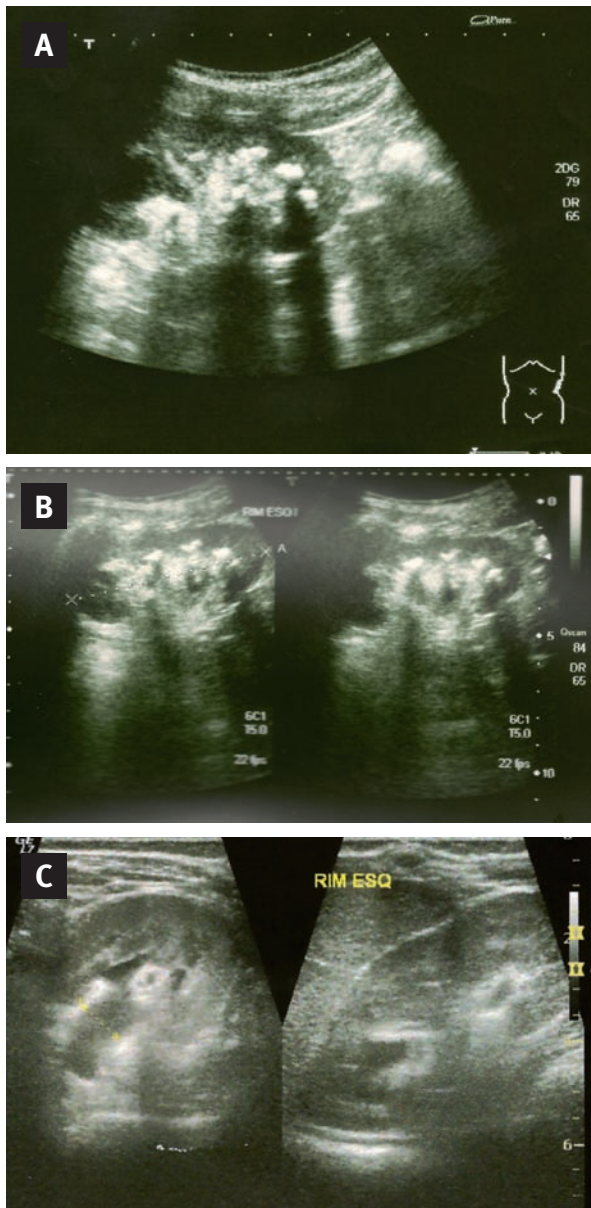
**Figure 1**

Renal ultrasonography. Staghorn calculus at left renal pelvis.



**Figure 2**

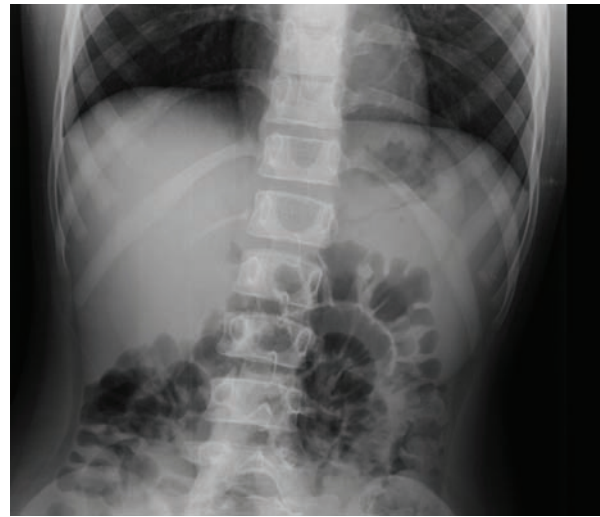Abdominal X-ray. Staghorn calculus at left renal pelvis and a round calculus at right renal pelvis.



**Figure 3**

Progressive fragmentation of the calculus after ESWL sessions.

After urine sterilisation, ESWL was performed, using the Dornier Lithotripter S II, during separate sessions on the left (five sessions, power between 1000-1600 shock waves, 16-25J) and right (one session, power 700 shock waves, 11J) with progressive fragmentation of the staghorn calculus (Fig. 3). In each session, the child was sedated to minimise



**Figure 4**

Following last ESWL treatment, the child is free of nephrolithiasis, as shown by X-ray.

patient movements (pain, respiration). Due to the higher power normally used (2000-4000 shock waves) in the standard equipment, we made some changes to minimise the impulse rate (bringing bags of water).

Following her last ESWL treatment, the child is free of nephrolithiasis, as shown by renal ultrasonography and conventional abdominal radiography performed at 3, 6, 12, 18 and 24 months (Fig. 4). DMSA renal scan performed at 24 months after her last ESWL treatment was normal.

## DISCUSSION

Although urolithiasis is rare in developed countries, association with UTI caused by urea-splitting bacteria is relatively common, but staghorn calculi have rarely been reported in this age group.

The aetiology of urolithiasis associated with UTI in infants is related to the presence of urease-producing bacteria, including *Proteus* (most common), *Klebsiella* and *Pseudomonas*, as reported in our case. The presence of urea-splitting bacteria leads to the hydrolysis of urea into ammonium and hydroxyl ions, and, consequently, alkalinisation of urine, which

can lead to the precipitation of magnesium and calcium phosphate. The diagnosis of lithiasis should be carefully considered in all children with *Proteus* UTI<sup>7-9</sup>.

Struvite calculi are frequently associated with urologic and metabolic abnormalities, such as VUR and hypercalciuria<sup>9</sup>. In the reported case, VUR grade II at the right was confirmed by VCUG, but the staghorn calculus was present in left renal pelvis. Due to the patient's young age and the extent of lithiasis, it was necessary to exclude any possible underlying metabolic disease.

The treatment of staghorn calculi consists of the removal of the stone, but this procedure is more technically demanding in infants than older children or adults due to the size of the kidneys, an increased chance of renal artery thrombosis secondary to aggressive renal mobilisation and more difficult percutaneous access with standard equipment<sup>10,11</sup>. Therefore, more than one treatment may be required to eradicate a large renal stone in an infant<sup>6</sup>. Data from current literature defined ESWL monotherapy as an efficient and safe modality for the treatment of staghorn calculi in children, with a low percentage of complications and subsequent surgical retreatments<sup>6,12-15</sup>. In the case reported, although the use of ESWL is controversial due to the risk of fragmentation and obstruction of urinary tract, it was performed with good outcome. Other acute complications of ESWL are UTI and renal haematoma. In this case, urine sterilisation was performed before ESWL and renal ultrasonography was performed after each session. Clinical studies in paediatric patients treated with ESWL have not consistently identified serious long-term consequences of ESW<sup>15,16</sup>. In the reported case, DMSA renal scan performed at 24 months after her last ESWL treatment was normal.

In conclusion, with this report, we emphasise the need to consider struvite calculi in all children with *Proteus* UTI. ESWL is an efficient and safe treatment of young children (<2 years) with urolithiasis and should be considered as the first option.

**Conflict of interest statement.** None declared.

## References

1. Areses-Trapote R, Urbietta Garagorri MA, Ubetagoyena-Arrieta M, Mingo-Monte T, Arruebarrena-Lizarraga D. Evaluación de la enfermedad renal litiasica. Estudio metabólico. *An Pediatr (Barc)* 2004;61:418-27
2. Hulton SA. Evaluation of urinary tract calculi in children. *Arch Dis Child* 2001;84:320-23
3. Anderson DA. Historical and geographical differences in the pattern of urinary stones considered in relation to possible aetiological factors. In: Hodgkinson A, Nordin BEC eds. *Renal Stone Research Symposium*. London: Churchill, 1969;7-31
4. Begun FP, Foley WD, Peterson A. Urolithiasis – patient evaluation. *Urol Clin North Am* 1997;24:97-116
5. Ghazali S, Barratt TM, Williams DI. Childhood urolithiasis in Britain. *Arch Dis Child* 1973;48:291-95
6. Rassweiler JJ, Renner C, Eisenberger F. Management of Staghorn Calculi: Critical Analysis After 250 Cases. *Brazilian Journal of Urology* 2000;26:463-78
7. Griffith DP, Osborne CA. Infection (urease) stones. *Miner Electrolyte Metab* 1987;13:278-85
8. Miano R, Germani S, Vespasiani G. Stones and urinary tract infections. *Urol Int* 2007;79:32-6
9. Bichler KH, Eipper E, Naber K. Infection-induced urinary stones. *Urologe A* 2003;42:47-55
10. Burns JR, Joseph DB. Combination therapy for a partial staghorn calculus in an infant. *J Endourol* 1993;7:469-71
11. Netto JM, Perez LM, Batista LR, Roya SA, Burns JR. Bilateral staghorn calculi in an eighteen-month-old boy. *ScientificWorldJournal* 2004;4:249-52
12. Castagnetti M, Rigamonti W. Extracorporeal shock wave lithotripsy for the treatment of urinary stones in children. *Arch Ital Urol Androl* 2010;82:49-50
13. Al-Busaidy SS, Prem AR, Medhat M. Pediatric staghorn calculi: the role of extracorporeal shock wave lithotripsy monotherapy with special reference to ureteral stenting. *J Urol* 2003;169(2):629-33
14. Goktas C, Akca O, Horuz R, Gokhan O, Albayrak S, Sarica K. SWL in lower calyceal calculi: evaluation of the treatment results in children and adults. *Urology* 2011;78(6):1402-6
15. D'Addessi A, Bongiovanni L, Racioppi M, Sacco E, Bassi P. Is extracorporeal shock wave lithotripsy in pediatrics a safe procedure? *J Pediatr Surg* 2008;43(4):591-6
16. Nelson CP. Extracorporeal shock wave lithotripsy in the pediatric population. *Urol Res* 2010;38:327-31

## Correspondence to:

Dr António V. Silva  
Department of Paediatrics, CHGE  
Rua Doutor Francisco Sá Carneiro  
4400-129 Vila Nova de Gaia, Portugal  
vinhasdasilva@gmail.com